

# Low-intensity indocyanine-green laser phototherapy of acne vulgaris: Pilot study

**Elina A. Genina**  
**Alexey N. Bashkatov**  
**Georgy V. Simonenko**

Saratov State University  
Optics Department  
Astrakhanskaya 83  
Saratov 410026  
Russia  
E-mail: eagenina@optics.sgu.ru

**Olga D. Odoevskaya**  
Saratov State Medical University  
Optics Department  
Saratov 410026  
Russia

**Valery V. Tuchin**  
Optics Department  
Astrakhanskaya 83  
Saratov 410026  
Russia

**Gregory B. Altshuler**  
Palomar Medical Technologies  
Research and Development Department  
82 Cambridge St  
Burlington, MA 01803-4107

## 1 Introduction

Acne vulgaris is a skin disease affecting more than 80% of young people and is the most common skin disease seen in dermatological practice.<sup>1,2</sup> This is a follicular disorder that affects pilosebaceous follicles, primarily of the face, neck, and upper trunk, and is characterized by both noninflammatory and inflammatory lesions. Hyperkeratosis with obstruction of the follicular opening, increased production of sebum (lipids secreted by the androgen-sensitive sebaceous glands), and proliferation of *Propionibacterium acnes* (*P. acnes*) leading to inflammation, play the main role in the development of the disease.<sup>2,3</sup> Despite the many effective treatments currently available for acne, there remain many patients who have problematic side effects.<sup>4–10</sup> Minocycline carries the uncommon risks of benign intracranial hypertension, lupus erythematosus-like syndromes, and hepatitis.<sup>6,7</sup> Oral isotretinoin frequently produces significant mucocutaneous symptoms and, less frequently, systemic symptoms such as myalgia, headaches, occasional depression, and other effects.<sup>1,8–11</sup> Topical retinoids are associated with irritant side effects, producing local erythema, dryness, peeling, burning, and itching, and causing increased sun sensitivity in the skin.<sup>12–15</sup> Furthermore, bacterial resistance to many antibacterial agents is an increasing problem.<sup>16–22</sup> There is therefore a need to develop different therapeutic methods for treatment of acne. The methods based in particular on light irradiation have been inten-

**Abstract.** Near infrared (NIR) diode laser low-intensity (soft) phototherapy with the topical application of indocyanine green (ICG) has been suggested for treatment of acne vulgaris. Twelve volunteers with acne lesions on their faces and/or backs were enrolled in the experiment. Skin areas of the subjects that were  $4 \times 5 \text{ cm}^2$  were stained with ICG solution for 5 min before laser irradiation (803 nm) at a power density up to  $50 \text{ mW/cm}^2$  for 5 to 10 min. For 75% of the subjects, a single treatment was provided and for the other 25%, eight sequential treatments over a period of a month were carried out. Observations a month after the completion of the treatment showed that only the multiple treatments with a combination of ICG and NIR irradiation reduced inflammation and improved the state of the skin for a month without any side effects. A month after treatment, the improvement was about 80% for the group receiving multiple treatments. Single treatments did not have a prolonged effect. © 2004 Society of Photo-Optical Instrumentation Engineers. [DOI: 10.1117/1.1756596]

Keywords: indocyanine green; NIR laser irradiation; photodynamic therapy; acne vulgaris.

Paper 03057 received Apr. 30, 2003; revised manuscript received Oct. 31, 2003; accepted for publication Nov. 12, 2003

sively studied.<sup>23–31</sup> Low-intensity light irradiation would be an alternative therapeutic technique for acne patients who have contraindications to the use of medications.

It has been shown that UV radiation has the potential to destroy *P. acnes in vitro*.<sup>23</sup> However, UVA radiation induces erythema and pigmentation, and can induce changes in surface lipids and thus enhance comedogenesis.<sup>24</sup> Phototherapy with visible light also has a beneficial effect on acne and avoids the potential risk of UV radiation.<sup>23–31</sup> It is known that *P. acnes* produces endogenous porphyrins, the major component of which is corpporphyrin III, which absorbs mainly visible light in the range of 400 to 415 nm.<sup>4,23,25,31</sup> The fluorescence emission spectrum of corpporphyrin can be observed with an emission maximum at 623 nm.<sup>31</sup> Recently it has been shown that irradiation of the affected skin with UV (390 nm), violet (405 nm), blue (415 nm), green (470 nm), white (full spectrum), and red (660 nm) light leads to an improvement in the state of the skin, with different degrees of effectiveness depending in the light wavelength and irradiation dose.<sup>23–33</sup> Violet and blue light are theoretically the most effective visible wavelengths for photoactivation of the major endogenous porphyrin component of *P. acnes*, but they have poor penetration depth into the skin.<sup>23,25,28,30</sup> Green light is also capable of activating porphyrins and may be more efficient because of a higher penetration into the skin.<sup>29</sup> Red light is less effective at photoactivating porphyrins, but penetrates more deeply into tissue.<sup>4,30</sup> In addition, red light may have wound-healing properties by influencing the release of proin-

Send all correspondence to Dr. Elina A. Genina, Saratov State University, Optics Department, Astrakhanskaya 83, Saratov 410026, Russian Federation. Tel: 7 8452 514693; E-mail: eagenina@optics.sgu.ru

inflammatory cytokines from macrophages, which stimulate fibroblast proliferation and the production of growth factors.<sup>30,32,33</sup> In this connection, a mixed low-intensity blue-red light phototherapy is effective treatment for mild to moderate acne vulgaris.<sup>30</sup> The doses for the light sources used did not exceed  $50 \text{ J/cm}^2$  to exclude unwanted effects on normal surrounding skin.<sup>29,30</sup> After 20 to 24 phototherapy sessions, the improvements in inflammatory lesion counts were on the order of 30% with violet, 63% with blue, 22% with green, 14 to 25% with white, and 76% with the combined blue-red light, respectively.<sup>4,29,30</sup>

To enhance photodynamic killing of bacteria and to provide effective modification of the sebaceous gland apparatus, exogenous or inductive-exogenous agents such as aminolevulinic acid (ALA) have been used. Topically applied ALA was converted into a potent photosensitizer, protoporphyrin IX, in human hair follicles and sebaceous glands.<sup>4,34</sup>

Photosensitizers (dyes) activated by visible and NIR laser irradiation are preferable owing to the high penetration depth of light within a tissue. For example, effective photoinactivation of *P. acnes* stained by methylene blue (MB) and irradiated in the red spectral range has been described.<sup>35,36</sup>

Indocyanine green (ICG) is a tricarboyanine dye used widely as a diagnostic aid in determining blood volume, cardiac output, hepatic function, etc.<sup>37–39</sup> Depending on the solvent and the concentration of the dye in the solution, the maximum absorption can be between 650 and 800 nm.<sup>37–39</sup> ICG injected or applied topically together with NIR laser irradiation (800 nm) has been used successfully to destroy tumors and cancer cell cultures.<sup>40–46</sup> A precise correspondence between the wavelength of the laser irradiation and the wavelength of the dye absorption provides high selectivity of photodynamic action. In addition to the dye, the broadband lamp irradiation can also excite many skin chromophores, which can be undesirable. Moreover, when irradiating large areas of skin, it is more effective to use powerful lasers than lamps. For example, the estimated power density provided by a diode laser (803 nm) with a moderate output power of 4 W used in this experiment for a beam spot diameter of 10 cm is  $50 \text{ mW/cm}^2$ . The 500-W halogen lamp with its optical power efficiency and broad spectral range can provide only about  $10 \text{ mW/cm}^2$  within the spectral band of ICG and the same irradiation area 10 cm in diameter. Therefore, the use of a laser with an irradiation wavelength that is in the dye's absorption band is preferable. Recent progress in the technology of light-emitting diodes (LEDs), especially the increase in their brightness, allows us to consider LED matrix irradiators as ideal light sources for light therapy using ICG and other photodynamic dyes.

The application of ICG and high-intensity diode laser irradiation for acne treatment was described recently as a new approach based on selective photothermolysis of the sebaceous glands.<sup>47,48</sup> For laser thermotherapy of acne, the following laser parameters were used: a wavelength of 810 nm, a 4-mm spot size, a 50-ms pulse duration, and a fluence of  $40 \text{ J/cm}^2$ . Ten sites on the backs of patients with active acne were treated. For staining the sebaceous gland, a topical 5% ICG microemulsion was used. The staining agent was applied to the skin surface for 24 h.<sup>47</sup> Two different protocols for selective photothermolysis of skin acne lesions were suggested in Ref. 48: (1) without surface cooling of the skin by

irradiating the skin site by a laser beam (803 nm) at  $9 \text{ J/cm}^2$  for 0.5 s in a 4-mm spot, and (2) with cooling of the skin surface by irradiating the skin site by a laser beam (809 nm) at  $100 \text{ J/cm}^2$  for 0.5 s in a 4-mm spot. To provide selectivity of photothermolysis, skin was stained with 1% ICG lotion for 15 min. Using the first and the second protocol, 20 and 10 acne elements (papules and pustules), respectively, were treated.<sup>48</sup> A local temperature rise has been achieved in tissue up to 80 to 90 °C that is sufficient for effective damage of enlarged sebaceous glands ( $\sim 200 \mu\text{m}$  in diameter).<sup>47–49</sup> To interact with NIR light penetrating deeply into tissue, sebaceous glands should be effectively targeted by ICG. Fortunately, it has been shown that topically applied ICG is effectively accumulated in sebaceous glands.<sup>47,48,50–52</sup>

We conducted this pilot study to test the use of ICG staining and soft NIR laser irradiation on sebaceous glands for the treatment of acne vulgaris.

## 2 Materials and Methods

### 2.1 Selection of Subjects

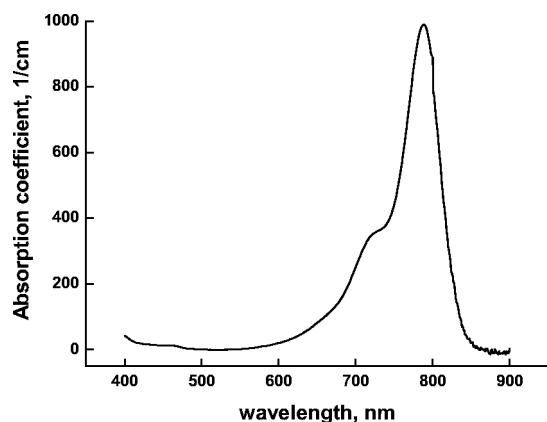
Twelve subjects of both sexes (5 males and 7 females) with acne vulgaris ranging from light to severe forms were enrolled between February and June 2001. The skin lesions were located on their faces or backs. The age of volunteers ranged from 17 to 27 years.

Possible subjects were excluded if they had used any topical acne treatment or systemic antibiotics in the past 2 months, or systemic retinoids in the past year. Persons who expected to have excessive sun exposure, or with a history of keloid or photosensitivity disorder, pregnant and lactating women, and mentally handicapped persons were also excluded.

### 2.2 Study Design

The subjects were randomly divided into single-treatment and multiple-treatment groups. The single-treatment group included eight volunteers: 3 males and 5 females. Among these, 3 patients had a light form, 3 had a moderate form, and 2 had a severe form of acne. Four volunteers (2 males and 2 females) were included in the multiple-treatment group. In this group, two patients had a light form, one patient had a moderate form, and one patient had a severe form of acne. Typically for each subject two symmetric areas of the affected skin site  $4 \times 5 \text{ cm}^2$  were chosen: one for the treatment and another for the control. The tested facial areas were the right and left cheek or the right and left half of a forehead. On the back, the sites were chosen according to the location of inflammatory elements. To ensure precise location of each tested area on the back, the sites were identified by a marker.

The ICG solution contained ethanol, glycerol, propylene glycol, and distilled water. The concentration of the dye in the solution was 1 mg/ml. Such a mixture of the solvent promoted better diffusion of the dye into the skin and sebaceous excretions. Moreover this mixture provided a high absorption coefficient (up to  $1000 \text{ cm}^{-1}$ ) at 789 nm (Fig. 1).<sup>52</sup> The solution was applied to the surface of the skin for 5 min. Before the application of ICG, the surface of the skin was thoroughly cleaned. After the application of ICG careful cleaning of the surface done to avoid blocking light radiation by the intensively stained upper layers of the skin and to avoid overheating



**Fig. 1** Absorption spectra of indocyanine green (ICG) at a concentration of 1 mg/ml in a glycerol-ethanol-propylene glycol-water solution.

ing these layers when laser irradiation was applied. Radiation (803 nm, up to  $50 \text{ mW/cm}^2$ ) by a diode laser (OPC-BO15-MMM-FCTS, Opto Power Corp., Tucson, Arizona) was applied to the stained area for 5 min for the patients with a light form of acne and 10 min for the patients with moderate to severe forms of acne. The doses of irradiation were 15 and  $30 \text{ J/cm}^2$ , respectively. The spot diameter was about 10 cm. When the affected area of the patient's back was rather large, four  $4 \times 5 \text{ cm}^2$  areas were selected: one was stained and irradiated; another was only stained; a third was only irradiated; and a fourth was untreated.

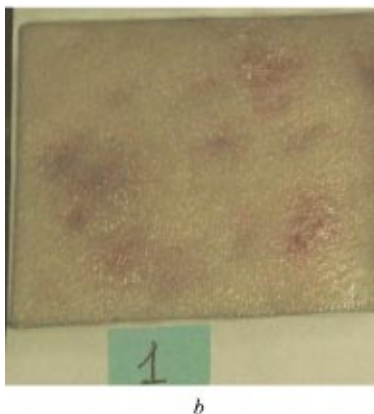
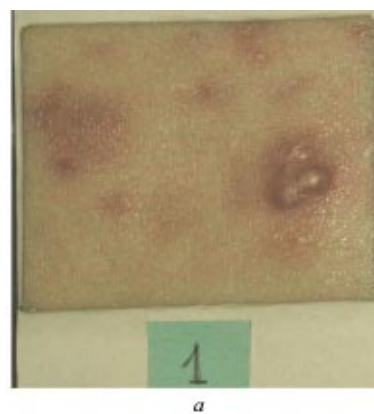
In the multiple-treatment group, the subjects were treated twice a week for four sequential weeks. Cumulative doses were 120 and  $240 \text{ J/cm}^2$ . In both groups clinical evaluations of the treatment results were carried out a week and a month after the last treatment. During the entire period of the treatment and observation the patients did not receive other therapy.

### 2.3 Analysis of the Results

A Nikon Coolpix990 (Japan) digital camera was used to take photographs of the treated and control sites of the skin. A linear polarization filter (Crystal Optics, Tokyo) was placed on the lens to reduce reflection from the skin's surface. The sites in the study were photographed at each visit of the patient during the treatment course and once a week during a month of observation.

The treatment effects were determined from an analysis of the photographed changes between (1) treated and untreated skin sites for each subject (two sites) and (2) the single- and multiple-treatment groups.

To estimate the state of a volunteer's skin impartially, photographs of both treated and control sites were given to two dermatologists for the analysis. They defined the total number of elements (comedones, papules, pustules, and nodules) on the tested sites before the treatment, a week and a month after the completion of the treatment, and the sizes of the elements for each subject. The number of active elements (without the comedones) was averaged for the same time period before and after treatment for all groups of volunteers with single and multiple treatments. The standard deviation was estimated.



**Fig. 2** The state of a volunteer's skin site (male, 23 years, with severe form of acne) after multiple treatment by ICG and NIR irradiation: (a) baseline and (b) 2 weeks later. The area is  $4 \times 5 \text{ cm}^2$ .

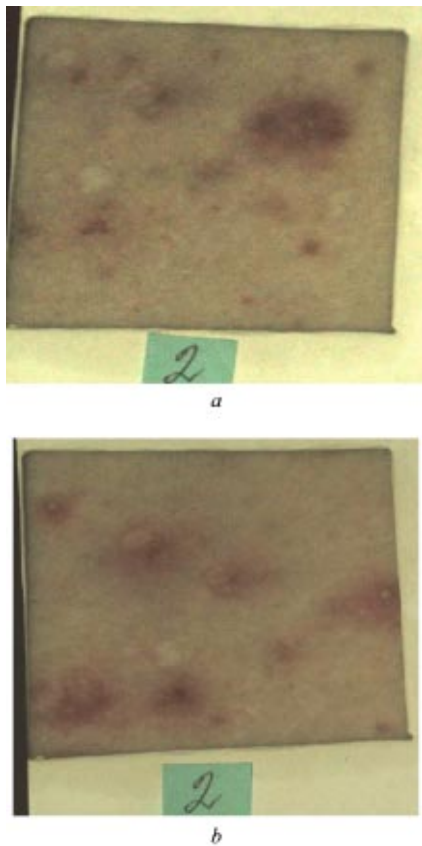
For an objective evaluation of the process of recovery, a study of microflora on the treated areas was carried out using a fluorescence technique. To test microflora fluorescence, skin excretions before and after acne phototreatment were collected on glass plates ( $2.5 \times 7.5 \text{ cm}^2$ ) and observed with a luminescence microscope (Lumam RPO-11, LOMO, St. Petersburg, Russia) integrated with a digital camera. To obtain a sample, the glass plate was pressed to the skin surface for a few seconds. The orange-red fluorescence (above 590 nm) was detected by the microscope with optical filters at excitations of 400 to 420 nm. The fluorescent images were captured.

## 3 Results and Discussion

The observations have shown that the combined action of ICG and NIR irradiation decreases the number of active elements (i.e., elements with active inflammatory processes; papules, pustules, and nodules) and their sizes, and causes flattening of the elements. It was noticed that the resolution of the papules into pustules on the tested area occurred more quickly. A week after the treatment, new elements such as papules and pustules did not appear in most cases. If the elements appeared, their sizes were smaller than the initial ones. On average, the inflammation process had a milder form.

The series of photos in Fig. 2, Fig. 3, Fig. 4, and Fig. 5 presents the images of four skin sites on the back of a subject after four treatments. Each site corresponds to a different treatment of the skin.

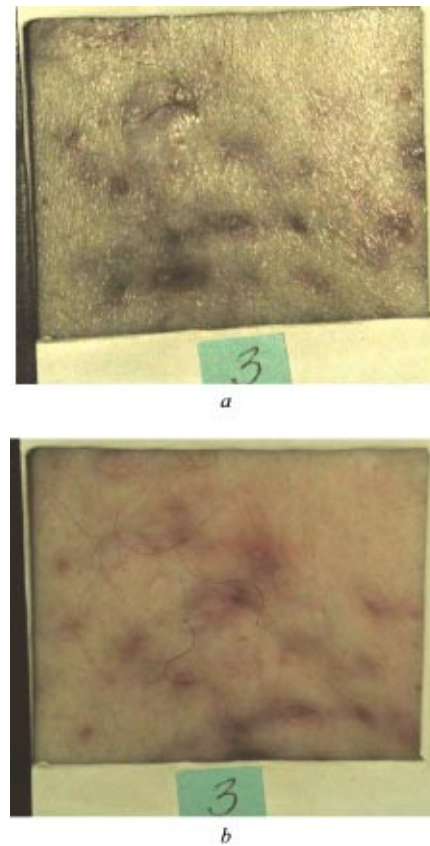




**Fig. 3** The state of a volunteer's skin (male, 23 years, with severe form of acne) at an untreated control site: (a) baseline and (b) 2 weeks later. The area is  $4 \times 5 \text{ cm}^2$ .

It is easily seen that only the skin site treated with ICG and NIR laser irradiation has shown a significant improvement in acne lesions 2 weeks after treatment. The active element in the form of three integrated papules has been transformed into a light macule [Figs. 2(a) and 2(b)]. New inflammation elements have not appeared at this site. The NIR-treated skin sites have not shown a significant difference from the baseline [Figs. 4(a) and 4(b)]. On both the control (without treatment) and ICG-treated sites, the skin has changed for the worse [Figs. 3(a) and 3(b) and Figs. 5(a) and 5(b)]. In these cases the papules have transformed into pustules.

The diagrams presented in Fig. 6 show the dynamics of the results obtained for the combined action of ICG and NIR irradiation for single and multiple acne treatments a week and a month after the completion of the treatment for all groups of patients. We have not divided the patients into groups in accordance with the degree of acne severity because of small number of representatives in each group. The height of the columns is equal to the mean number of the active elements on the tested sites of the skin. Comedones, macules, and scars were not counted. Comedones are not accompanied by an inflammatory process in the skin and therefore the treatment has no influence on their state. Macules and scars correspond to the postinflammatory process and remained on the skin for a long time. The bars correspond to the standard deviation from the mean value. The first group of columns corresponds to the initial state of the skin sites before the treatment, the



**Fig. 4** The state of a volunteer's skin site (male, 23 years, with severe form of acne) after multiple treatment by NIR irradiation alone: (a) baseline and (b) 2 weeks later. The area is  $4 \times 5 \text{ cm}^2$ .

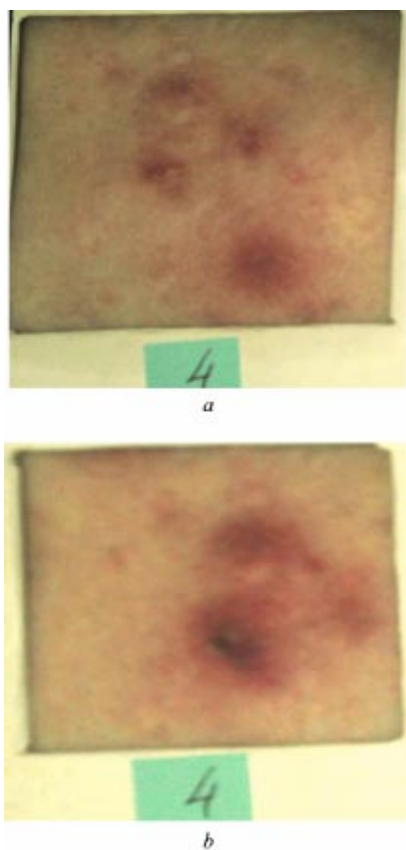
second one to the state of the same skin sites a week after the treatment, and the third to a month after the treatment.

It is clearly seen that in general the single treatment was positive but not very effective. Within 3 to 7 days after the treatment (ICG and NIR light), some improvement in the state of the patient's skin was observed. The diameter of the erythema area around the active elements decreased and the elements flattened and dried. However, then papules accompanied by erythema appeared on the treated areas.

In contrast, the multiple-treatment group has shown significantly higher improvement than the single-treatment one. The number of the active elements and the sizes of both elements and erythema areas around the elements have decreased significantly. This positive effect was retained for about a month after the completion of the procedures. After the single treatment, the positive effect lasted only a week.

It is known that dye penetrates into skin mainly through the hair canals. The region between the epidermal-dermal junction (open to the skin surface) and the intraepidermal infundibulum of a hair follicle is the path for ICG penetration. The upper part of a hair follicle, a so-called permanent portion, especially the sebaceous glands and the microorganisms they contain, are stained.<sup>50-52</sup> The photoactivation of ICG within the stained areas by diode laser irradiation ( $\sim 800 \text{ nm}$ ) produces photodynamic damage of pathogenic bacteria.

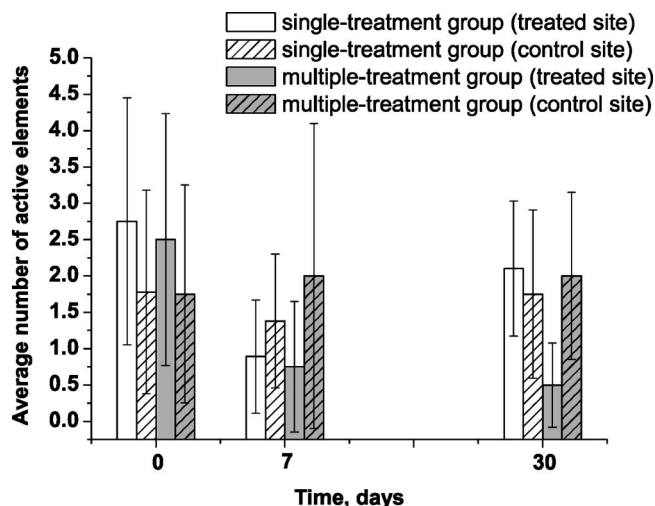
Figure 7 illustrates the possibility of objectively monitoring the results of acne treatment by detection of the fluores-



**Fig. 5** The state of a volunteer's skin site (male, 23 years, with severe form of acne) after multiple treatment by ICG alone (a) baseline and (b) 2 weeks later. The area is  $4 \times 5 \text{ cm}^2$ .

cence of skin excretion samples before and after treatment. Orange-red fluorescence allows recognition of *P. acnes* colonies taken from the skin site through excitation of bacteria-produced porphyrins. It is clear that after the treatment a much lower intensity and smaller areas of fluorescence can be observed on the samples of skin excretions. Therefore, low-intensity acne treatment is connected with photodynamic suppression of bacteria. Our direct model experiments have shown that even the smallest light dose (about 3 to 5  $\text{J}/\text{cm}^2$ ) is sufficient to damage ICG-stained microorganisms.<sup>53</sup> The absence of suppression when NIR laser irradiation only (without ICG) is used has been also shown.<sup>53</sup>

The results of acne treatment were more pronounced for moderate to severe groups of patients who had inflammatory elements. The combined action of ICG and laser radiation has shown better results than a course of antibiotic therapy. According to Cunliffe,<sup>2</sup> after 4 weeks of antibiotic therapy only a 10 to 20% improvement can be expected. The result of ICG-light action is seen in 3 to 7 days: about a 72.4% improvement for the single-treatment group and about 70% for the multiple-treatment group. Acne recovery occurred from 7 to 10 days after a single treatment for all patients. The improvement in single-treated skin was only 23.6% a month after the treatment. With an increase in the number of procedures, the recovery period lasted longer than a month. In a month the improvement was about 80% for the multiple-treatment group.



**Fig. 6** Comparable statistical analysis of the state of volunteers' skin after single and multiple treatments showing the state for all groups of volunteers. The vertical axis is the mean number of active acne elements counted within the control and treated with ICG lotion and NIR irradiation of skin areas of  $4 \times 5 \text{ cm}^2$ . The horizontal axis is the time scale: the first group of columns corresponds to the initial status of the skin sites; the second group corresponds to the same skin sites a week after the treatment; and the third group is a month after the treatment. The bars reflect standard deviations.

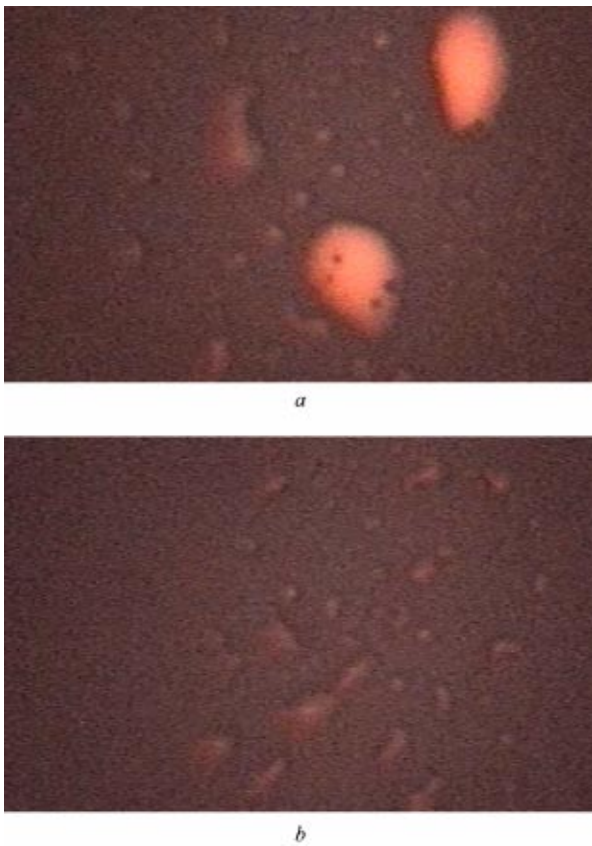
Low-intensity acne therapy has a bacterial suppression effect and does not seriously influence the sebum excretion rate and follicle ductal hyperkeratinization. An improvement in patients with a light form of acne, having mainly open and closed comedones, was not observed. The absence of influence of the combined ICG-light treatment on the comedones is explained apparently by the low power density of laser irradiation. An irradiation dose in the range of 15 to 30  $\text{J}/\text{cm}^2$  can be sufficient to kill bacteria but is not enough to damage keratinocytes.

ICG can be effectively bound by melanin, owing to melanin's unique high-affinity sites for binding a large number of organic molecules, including dyelike materials.<sup>54</sup> In this connection there are expected additional targets and paths for ICG staining of acne lesions, such as blackheads (an open comedon consisting of a plugged sebum gland with melanin or oxidized melanin) or the rupture of a sebum gland (invasion of a sebum-microorganism mixture in the surrounding matrix). Thus, by increasing the power density of irradiation, skin damaged by comedones can be improved.

Numerous studies support the view that inflammatory processes have a key role in the development of acne.<sup>23,25,28-30,36,55</sup> The inhibition of *P. acnes* and other accompanying bacterial cultures that induce inflammation causes prolonged improvement of the skin and can be a supplementary method in treating acne.

During the laser treatment, the patients felt a slight warmth. There were no complaints of pain or other discomfort. Visible changes on the treated skin surface were not observed during and immediately after the treatment.

Side effects such as erythema, edema, hypopigmentation and hyperpigmentation, blistering, superficial exfoliation, and crusting usually arise at much higher light power densities



**Fig. 7** Fluorescence images of skin excretion on a glass plate from a patient with acne vulgaris (a) before and (b) after treatment with ICG lotion and NIR laser irradiation. An orange-red fluorescence (above 590 nm) can be seen at 400 to 420-nm excitation.

than those used in this study.<sup>34,47,56</sup> These effects are possibly the result of thermal injury of epidermal tissue and sebaceous glands closely associated with hair follicles.<sup>48,50,57</sup> Photodynamic therapy with a topical application of aminolevulinic acid and a broadband light source (550 to 700 nm) is more radical, but also has significant side effects. It produces partial or complete necrosis of sebaceous glands.<sup>34</sup>

In our study we did not observe any adverse effects because of the rather small power densities of irradiation. However, positive dynamics of acne treatment was observed. To increase effectiveness of the treatment, it is possible to use higher power densities for irradiation.<sup>47,48</sup> The power density has to be limited by the thermal sensitivity of the patient's skin because ICG has high absorbance and consequently using lower irradiation densities than for unstained skin may cause pain, burns, blistering, etc. However, this complication of the technique can be overcome by careful cleaning of the skin's surface and optimization of the staining procedure.<sup>52</sup>

#### 4 Conclusion

This study was a pilot investigation that tested the combined action of ICG and soft NIR irradiation on the development of such skin diseases as acne vulgaris. The results of the treatment were more pronounced for patients with moderate to

severe forms of acne. With an increase in the number of procedures, the positive effect of the treatment was more prolonged.

The hypothesis that suppression of microflora is a leading result of laser low-intensity treatment is supported by the reduction or complete resolution of the inflammatory response in the dermis and epidermis surrounding the follicles affected by acne. Side effects were not observed. It is expected that somewhat higher power densities and exposures of laser irradiation will promote more prolonged action of such photodynamic therapy without any side effects. Future studies will compare the effectiveness of antibiotics, retinoids, ALA, and photodynamic acne therapy with the proposed new approach.

#### Acknowledgments

The authors are grateful to Palomar Medical Products, Inc. for funding this work and providing the diode IR laser and Nikon Coolpix 990 digital camera. The research was also supported by a grant from the Russian Federation President for support of Leading Scientific Schools no. 25.2003.2; by award no. REC-006, and Basic Research and Higher Education Post-Doctoral Fellowship Annex of U.S. Civilian Research & Development Foundation for the Independent States of the Former Soviet Union (CRDF); by contract no. 40.018.1.1.1314 of the Ministry of Industry, Science and Technologies of the Russian Federation; and by the Ministry of Education of the Russian Federation. The authors are grateful to Prof. J. Lademann for his critical notes and to Dr. S. V. Eremina (Saratov State University) for help in translating the manuscript into English.

#### References

1. W. J. Cunliffe and N. B. Simpson, "Disorders of the sebaceous glands," in *Textbook of Dermatology*, R. H. Champion, J. L. Burton, D. A. Burns, and S. M. Breathnach, Eds., Blackwell Science, Oxford (1998).
2. W. J. Cunliffe, *Acne*, Martin Dunitz, Year Book Medical Publishers, Chicago (1989).
3. V. P. Adaskevich, *Acne and Rosacea*, Olga, St. Petersburg (2000).
4. W. J. Cunliffe and V. Goulden, "Phototherapy and acne vulgaris," *Br. J. Dermatol.* **142**, 853–856 (2000).
5. A. L. Wright and G. B. Colver, "Tetracyclines—how safe are they?" *Clin. Exp. Dermatol.* **13**, 57–61 (1988).
6. M. Pepine, F. P. Flowers, and F. A. Ramos-Caro, "Extensive cutaneous hyperpigmentation caused by minocycline," *J. Am. Acad. Dermatol.* **28**, 292–295 (1993).
7. A. Gough, S. Chapman, K. Wagstaff et al., "Minocycline-induced autoimmune hepatitis and systemic lupus erythematosus-like syndrome," *Br. Med. J.* **320**, 169–172 (1996).
8. R. S. Stern, "When a uniquely effective drug is teratogenic: the case of isotretinoin," *New Engl. J. Med.* **320**, 1007–1009 (1989).
9. J. P. Griffin, "A review of the literature on benign intracranial hypertension associated with medication," *Adverse Drug Reactions Toxicol. Rev.* **11**, 41–58 (1992).
10. C. Hong Ng and I. Schweitzer, "The association between depression and isotretinoin use in acne," *Austral. N. Zeal. J. Psychiat.* **37**, 78–84 (2003).
11. K. Charalabopoulos, V. Papalimneos, A. Charalabopoulos, and J. Hatzis, "Two new adverse effects of isotretinoin," *Br. J. Dermatol.* **148**, 593 (2003).
12. A. H. Lewin, M. E. Bos, F. C. Zusi, X. Nair, G. Whiting, P. Bouquin, G. Tetrault, and F. I. Carroll, "Evaluation of retinoids as therapeutic agents in dermatology," *Pharmaceut. Res.* **11**(2), 192–200 (1994).
13. J. Czernielewski, S. Michel, M. Bouclier et al., "Adapalene biochemistry and the evolution of a new topical retinoid for treatment of acne," *JEADV* **15**, 5–12 (2001).



14. J. E. Wolf, "An update of recent clinical trials examining adapalene and acne," *JEADV* **15**, 23–29 (2001).
15. S. Bershad, G. K. Singer, J. E. Parente et al., "Successful treatment of acne vulgaris using a new method: results of a randomized vehicle-controlled trial of short-contact therapy with 0.1% tazarotene gel," *Arch. Dermatol.* **138**, 481–489 (2002).
16. L. A. Drake, "Guidelines of care for acne vulgaris," *J. Am. Acad. Dermatol.* **22**, 676–680 (1990).
17. E. A. Eady, M. R. Farmery, J. I. Ross et al., "Effects of benzoyl peroxide and erythromycin alone and in combination against antibiotic-sensitive and -resistant skin bacteria from acne patients," *Br. J. Dermatol.* **131**, 331–336 (1994).
18. J. J. Leyden, K. J. McGinley, S. Cavalieri, G. F. Webster, O. H. Mills, and A. M. Kligman, "*Propionibacterium acnes* resistance to antibiotics in acne patients," *J. Am. Acad. Dermatol.* **8**, 41–45 (1983).
19. E. A. Eady, C. E. Jones, J. L. Tipper, J. H. Cove, W. J. Cunliffe, and A. M. Layton, "Antibiotic resistant propionibacteria in acne: need for policies to modify antibiotic usage," *Br. Med. J.* **306**, 555–556 (1993).
20. J. T. Magee and E. L. Pitchard, "Antibiotic prescribing and antibiotic resistance in community practice: Retrospective," *Br. Med. J.* **319**, 1239–1240 (1999).
21. J. J. Leyden, "Current issues in antimicrobial therapy for the treatment of acne," *JEADV* **15**, 51–55 (2001).
22. A. J. Cooper, "Treatment of acne with isotretinoin: recommendations based on Australian experience," *Australasian J. Dermatol.* **44**, 97–105 (2003).
23. B. Kjeldstad and A. Johnsson, "An action spectrum for blue and near ultraviolet inactivation of *Propionibacterium acnes*; with emphasis on a possible porphyrin photosensitization," *Photochem. Photobiol.* **43**, 67–70 (1986).
24. O. H. Mills, M. Porte, and A. M. Kligman, "Enhancement of comedogenic substances by ultraviolet radiation," *Br. J. Dermatol.* **98**, 145–148 (1978).
25. H. Meffert, K. Gaunitz, T. Gutewort, and U. J. Amlong, "Therapy of acne with visible light. Decreased irradiation time by using a blue-light high-energy lamp," *Dermatol. Monatsschr.* **176**(10), 597–603 (1990).
26. Z. Malik, H. Ladan, B. Ehrenberg, and Y. Nitzan, "Bacterial and viral photodynamic inactivation," in *Photodynamic Therapy: Basic Principles and Clinical Applications*, B. Henderson and T. Dougherty, Eds., pp. 97–113, Marcel Dekker, New York (1992).
27. G. Jori and D. Tonlorenzy, "Photodynamic treatment of microbial infections," *Photodynamic News* **2**(1), 2–3 (1999).
28. A. R. Shalita, Y. Harth, M. Elman, M. Slatkine, G. Talpalariu, Y. Rosenberg, A. Korman, and A. Klein, "Acne phototherapy using UV-free high-intensity narrow-band blue light: 3 center clinical study," *Proc. SPIE* **4244**, 61–73 (2001).
29. V. Sigurdsson, A. C. Knulst, and van H. Weelden, "Phototherapy of acne vulgaris with visible light," *Dermatology* **194**, 256–260 (1997).
30. P. Papageorgiou, A. Katsambas, and A. Chu, "Phototherapy with blue (415 nm) and red (660 nm) light in the treatment of acne vulgaris," *Br. J. Dermatol.* **142**, 973–978 (2000).
31. K. Arakane, A. Ryu, C. Hayashi, T. Masunaga, K. Shinmoto, S. Mashiko, T. Nagano, and M. Hirobe, "Singlet oxygen ( $^1\Delta_g$ ) generation from coproporphyrin in *Propionibacterium acnes* on irradiation," *Biochem. Biophys. Res. Commun.* **223**, 578–582 (1996).
32. S. Yong, P. Bolton, M. Dyson et al., "Macrophage responsiveness to light therapy," *Lasers Surg. Med.* **9**, 497–505 (1989).
33. W. Yu, J. O. Naim, and K. J. Lonzafame, "Effects of photostimulation on wound healing in diabetic mice," *Lasers Surg. Med.* **20**, 56–63 (1997).
34. W. Hongcharu, C. R. Taylor, Y. Chang, D. Aghassi, K. Suthamjariya, and R. R. Anderson, "Topical ALA-photodynamic therapy for the treatment of acne vulgaris," *J. Invest. Dermatol.* **115**, 183–192 (2000).
35. K. Koenig and H. Meyer, "Photodynamic activity of methylene blue," *Akt. Dermatol.* **19**, 195–198 (1993).
36. K. Koenig, M. Teschke, S. Eick, W. Pfister, H. Meyer, and K.-J. Halhuber, "Photodynamical inactivation of *Propionibacterium acnes*," *Proc. SPIE* **3247**, 106–110 (1998).
37. I. J. Fox and E. H. Wood, "Indocyanine green: physical and physiologic properties," *Staff Meetings of the Mayo Clinic* **35**(25), 732–744 (1960).
38. F. J. Green, *The Sigma-Aldrich Handbook of Stains, Dyes and Indicators*, Aldrich Chemical Co., Milwaukee, WI (1990).
39. S. L. Jacques's website: www.omlc.ogi.edu.
40. H. I. Pass, "Photodynamic therapy in oncology: mechanisms and clinical use," *J. Natl. Cancer Inst.* **85**, 443–456 (1993).
41. W. R. Chen, R. L. Adams, S. Heaton, D. T. Dickey, K. E. Bartels, and R. E. Nordquist, "Chromophore-enhanced laser-tumor tissue photothermal interaction using an 808-nm diode laser," *Cancer Lett.* **88**, 15–19 (1995).
42. W. R. Chen, R. L. Adams, K. E. Bartels, and R. E. Nordquist, "Chromophore-enhanced *in vivo* tumor cell destruction using an 808-nm diode laser," *Cancer Lett.* **94**, 125–131 (1995).
43. W. R. Chen, R. L. Adams, A. K. Higgins, K. E. Bartels, and R. E. Nordquist, "Photothermal effects on mammary tumor using indocyanine green and an 808-nm diode laser: *in vivo* efficacy study," *Cancer Lett.* **98**, 169–173 (1996).
44. S. Fickweiler, R. M. Szeimies, W. Baumler, P. Steinbach, S. Karrer, A. E. Goetz, C. Abels, F. Hofstadter, and M. Landthaler, "Indocyanine green: intracellular uptake and phototherapeutic effects *in vitro*," *J. Photochem. Photobiol. B Biol.* **38**, 178–183 (1997).
45. W. Baumler, C. Abels, S. Karrer, T. Weis, H. Messmann, M. Landthaler, and R.-M. Szeimies, "Photo-oxidative killing of human colonic cancer cells using indocyanine green and infrared light," *Br. J. Cancer* **80**(3/4), 360–363 (1999).
46. C. Abels, S. Fickweiler, P. Weiderer, W. Baumler, F. Hofstadter, M. Landthaler, and R.-M. Szeimies, "Indocyanine green (ICG) and laser irradiation induce photooxidation," *Arch. Dermatol. Res.* **292**, 404–411 (2000).
47. J. R. Lloyd and M. Mirkov, "Selective photothermolysis of the sebaceous glands for acne treatment," *Lasers Surg. Med.* **31**, 115–120 (2002).
48. V. V. Tuchin, E. A. Genina, A. N. Bashkatov, G. V. Simonenko, O. D. Odoevskaya, and G. B. Altshuler, "A pilot study of ICG laser therapy of *acne vulgaris*: photodynamic and photothermolysis treatment," *Lasers Surg. Med.* **33**, 296–310 (2003).
49. J. Pearce and S. Thomsen, "Rate process analysis of thermal damage," in *Optical-Thermal Response of Laser-Irradiated Tissue*, A. J. Welch and M. J. C. Van Gemert, Eds., Plenum, New York (1995).
50. E. A. Genina, A. N. Bashkatov, Yu. P. Sinichkin, V. I. Kochubey, N. A. Lakodina, O. A. Perepelitzina, G. B. Altshuler, and V. V. Tuchin, "*In vitro* and *in vivo* study of dye diffusion into the human skin and hair follicles," *Proc. SPIE* **4162**, 63–70 (2000).
51. I. V. Fedosov, D. A. Zimnyakov, V. V. Tuchin, E. A. Genina, and G. B. Altshuler, "Double-wavelength laser scanning microphotometer (DWLSM) for *in vitro* hair shaft and surrounding tissue imaging," *Proc. SPIE* **4244**, 152–155 (2001).
52. E. A. Genina, A. N. Bashkatov, Yu. P. Sinichkin, V. I. Kochubey, N. A. Lakodina, G. B. Altshuler, and V. V. Tuchin, "*In vitro* and *in vivo* study of dye diffusion into the human skin and hair follicles," *J. Biomed. Opt.* **7**(3), 471–477 (2002).
53. V. V. Tuchin, I. S. Ovchinnikov, D. E. Popov, and G. B. Altshuler, "ICG-LED (810 nm) photodynamic inactivation of bacterial microorganisms," *J. Technical Phys. Lett.* (in press).
54. K. Jimbow, W. C. Quevedo, T. B. Fitzpatrick Jr., and G. Szabo, "Biology of melanocytes. Dermatology," in *General Medicine*, T. B. Fitzpatrick Jr., A. Z. Eisen, K. Wolff, I. M. Freedberg, and K. F. Austen, Eds., McGraw-Hill, New York (1993).
55. C. C. Zouboulis, "Exploration of retinoid activity and the role of inflammation in acne: issues affecting future directions for acne therapy," *JEADV* **15**, 63–67 (2001).
56. C. A. Nanni and T. S. Alster, "Laser-assisted hair removal: side effects of Q-switched Nd:YAG, long-pulsed ruby and alexandrite lasers," *J. Am. Acad. Dermatol.* **41**(2), 165–171 (1999).
57. W. Manuskiatti, C. C. Dierickx, S. Gonzalez, T.-Y. D. Lin, V. B. Campos, E. Gonzalez, and R. R. Anderson, "Laser hair removal affects sebaceous glands and sebum excretion: a pilot study," *J. Am. Acad. Dermatol.* **41**(2), 176–180 (1999).