

Journal of Biomedical Optics

BiomedicalOptics.SPIEDigitalLibrary.org

Measuring skin aging using optical coherence tomography *in vivo*: a validation study

Carina Trojahn
Gabor Dobos
Claudia Richter
Ulrike Blume-Peytavi
Jan Kottner

Measuring skin aging using optical coherence tomography *in vivo*: a validation study

Carina Trojahn, Gabor Dobos, Claudia Richter, Ulrike Blume-Peytavi, and Jan Kottner*

Charité-Universitätsmedizin Berlin, Clinical Research Center for Hair and Skin Science, Department of Dermatology and Allergy, Charitéplatz 1, Berlin 10117, Germany

Abstract. Dermal and epidermal structures in human skin change during intrinsic and extrinsic aging. Epidermal thickness is one of the most often reported parameters for the assessment of skin aging in cross-sectional images captured by optical coherence tomography (OCT). We aimed to identify further parameters for the non-invasive measurement of skin aging of sun-exposed and sun-protected areas utilizing OCT. Based on a literature review, seven parameters were inductively developed. Three independent raters assessed these parameters using four-point scales on images of female subjects of two age groups. All items could be detected and quantified in our sample. Interrater agreement ranged between 25.0% and 83.3%. The item scores “stratum corneum reflectivity,” “upper dermal reflectivity,” and “dermoepidermal contrast” showed significant differences between age groups on the volar and dorsal forearm indicating that they were best able to measure changes during skin aging. “Surface unevenness” was associated with the skin roughness parameters, R_z and R_{max} , on the inner upper arm and volar forearm supporting the criterion validity of this parameter on sun-protected skin areas. Based on the interrater agreement and the ability to differentiate between age groups, these four parameters are being considered as the best candidates for measuring skin aging in OCT images. © 2015 Society of Photo-Optical Instrumentation Engineers (SPIE) [DOI: [10.1117/1.JBO.20.4.045003](https://doi.org/10.1117/1.JBO.20.4.045003)]

Keywords: optical coherence tomography; clinical assessment; skin microtopography; skin aging.

Paper 150100R received Feb. 20, 2015; accepted for publication Mar. 26, 2015; published online Apr. 15, 2015.

1 Introduction

Skin aging is the continuous change of the skin's structure and functional capacity. In addition to the “normal” course of intrinsic or chronological aging, environmental (e.g., sun light) and life style (e.g., smoking) factors contribute to the so-called extrinsic skin aging. Skin areas that are predominantly exposed to ultra violet radiation (e.g., face, hands, and dorsal aspect of the forearm) are prone to develop various signs of extrinsic aging. These include deep wrinkles, loss of elasticity, and changes in skin pigmentation. Histologically, extrinsically aged skin shows degenerated collagen and elastic fibers in the upper and middermis, which is referred to as solar elastosis.¹⁻³

Facial appearance contributes to the perceived age of individuals and is an indicator of overall health.^{4,5} Thus, there is growing interest in skin aging research and so-called antiaging strategies. The evaluation of cosmetic products and rejuvenation procedures is often based on histological assessments that provide knowledge of the morphological and molecular characteristics of the skin.^{6,7} However, the invasive procedure to obtain biopsies contains disadvantages, such as tissue destruction, pain and an increased risk for infections.

Optical coherence tomography (OCT) allows a noninvasive and rapid cross-sectional visualization of the skin. It is a widely applied imaging method in many fields of dermatology,^{8,9} for instance, to follow up wound healing, to diagnose skin cancer, or to assess the effectiveness of skin care products.¹⁰⁻¹³ To date, only a few studies have used OCT to investigate skin aging. The most often reported parameter in skin aging research measured

in OCT images is epidermal thickness (ET). ET has been often observed to decrease with age on intrinsically and extrinsically aged skin areas.¹⁴⁻¹⁶ However, OCT images obviously provide much more information than ET only. Therefore, the idea emerged, whether there are other traits or criteria that might be used to characterize signs of skin aging in OCT images. The aim of this study was to develop and to evaluate possible additional parameters to measure skin aging using OCT.

2 Methods

2.1 Study Design and Participants

An exploratory validation study was conducted at the Clinical Research Center for Hair and Skin Science, Department of Dermatology and Allergy, Charité-Universitätsmedizin Berlin, Germany, between January and April 2014. Caucasian women of two age groups with healthy skin were recruited. Written informed consent was obtained from all subjects before participation. They were instructed not to use any cosmetic products on their arms at least 12 h prior to the measurements.

2.2 OCT Measurements

The OCT system Telesto (Thorlabs, Lübeck, Germany) was used in this study for *in vivo* evaluation of skin aging. This measurement method is based on the detection of the optical path length differences of reflected and backscattered light of a sample and a reference beam (interferometry). The OCT system contains a low-coherence near infrared (about 1300 nm)

*Address all correspondence to: Jan Kottner, E-mail: jan.kottner@charite.de

light source and a spectrometer that detects the phase delay of the wavelengths. The hand-held OCT probe was positioned directly onto the skin. Two-dimensional images were acquired with a scan length of around 10 mm, a lateral resolution of up to 8 μm , and a maximum penetration depth of around 1.5 mm.

ET was measured using the software ImageJ and a plug-in developed by Thorlabs. ET measurements were performed on three predefined measurement sites (center of the image and two lateral sites with a fixed distance to the center) by height-width titration, which is the length of a vertical line against the image *per se*.¹⁶ The average ET was calculated from these three measurements. All ET measurements were made by two investigators blinded to the participants' ages and skin areas.

2.3 OCT Items and Score Development

In order to develop possible detectable characteristics of skin aging, a literature review was conducted in Medline. Studies that applied different skin imaging techniques, such as sonography,¹⁷ histology,¹⁰ and laser scanning microscopy,¹⁸ as well as studies reporting features of skin morphology,¹⁹ wound healing,^{10,20} and pressure ulcer development¹⁷ were reviewed. Based on these reports, seven possible characteristics were developed inductively and iteratively by the authors. The items were discussed with a physician and a researcher, both experienced in OCT imaging, and further adapted. The preliminarily determined items were defined as follows: (1) "stratum corneum (SC) reflectivity," (2) "epidermal reflectivity," (3) "upper dermal reflectivity," and (4) "lower dermal reflectivity." These four "reflectivity" items describe the intensity of the signal detected by the camera backscattered from the respective tissues. (5) "Dermoepidermal contrast" describes the ability to distinguish between epidermis and dermis. (6) "Vessel density" is the absence or presence of dermal vessels, which were identified as elongated hyporeflective structures in the lower dermis. (7) "Surface unevenness" was defined as the degree to which the skin surface appears to be uneven or folded.

In a next step, OCT images taken from the right inner upper arm, right volar forearm, and right dorsal forearm of each participant were evaluated by three raters experienced in OCT imaging (two blinded to the participants' ages and one unblinded author) independently from each other. The raters were trained by the first author on item scale definitions using example images not included in the current analysis. Each item was graded using a four-point scale (0, absent; 1, low; 2, moderate; 3, high), except "vessel density," which was graded using a four-point scale ranging from 0 = no vessels to 3 = many vessels. This four category classification was applied to avoid a neutral position and to ensure differentiation.²¹

2.4 Criterion Validation of the Item "Surface Unevenness"

Criterion validity of the item "surface unevenness" was explored by correlating the score with instrumental measures of the skin microtopography of the identical skin areas. The Visioscan® VC 98 camera and the corresponding software SELS 2000 (both Courage & Khazaka Electronic GmbH, Cologne, Germany) were used to measure the DIN/ISO parameters R_z (arithmetic mean roughness from five consecutive sampling lengths) and R_{max} (maximal roughness). Both parameters were chosen because they exhibited the highest reliability in comparable age groups.^{22,23} Roughness measurements were conducted in

a controlled room temperature of $22 \pm 2^\circ\text{C}$ and $50\% \pm 10\%$ relative humidity and after the participants' acclimatization for at least 30 min.

2.5 Statistical Analysis

Demographic characteristics of the sample were described using means, standard deviations (SD), ranges, and frequencies. OCT item scores were analyzed descriptively using medians and interquartile ranges. Interrater agreement (p_o) of item scores between the three raters was calculated. This expresses the proportion in percent of which the three raters achieved identical results per OCT image.²⁴ Construct validity was evaluated using Mann-Whitney U tests to compare medians of the item scores between the two age groups per skin area. ET and skin surface roughness were presented as means and SDs. Group comparisons were performed using student's t test for independent samples. Criterion validity was tested using Spearman's correlation coefficients (r_s) between the OCT item score "surface unevenness" and skin roughness measurements R_z and R_{max} . A p -value of <0.05 (two-sided) was considered statistically significant. Statistical analysis was performed using IBM SPSS Statistics, Version 22.0 (IBM Corp., Armonk, New York).

3 Results

3.1 Sample Characteristics

Demographic characteristics of the study sample are summarized in Table 1. Sixteen female subjects were included in the validation study, eight subjects in the young group [mean age 33.5 (SD 2.1) years] and eight subjects in the old group [mean age 76.6 (SD 1.9) years]. Mean body mass indices were 21.8 (SD 2.0) kg/m^2 and 26.2 (SD 2.5) kg/m^2 . Equal distributions of Fitzpatrick phototypes II and III were observed in both groups.

3.2 Epidermal Thickness

Mean ET ranged from 64.8 μm on the dorsal forearm to 78.1 μm on the inner upper arm of the young group (Table 2). Differences between age groups were not statistically significant.

Table 1 Sample characteristics.

		Young group ($n = 8$)	Old group ($n = 8$)
Age in years	Mean (SD)	33.5 (2.1)	76.6 (1.9)
	range	31 to 37	74 to 79
BMI in kg/m^2	Mean (SD)	21.8 (2.0)	26.2 (2.5)
	range	19.7 to 25.9	21.1 to 29.3
Phototype, n	II	4	4
	III	4	4

Note: BMI, body mass index and SD, standard deviation.

Table 2 Epidermal thickness (μm) measured in optical coherence tomography (OCT) images.

	Young group	Old group	<i>p</i> value ^a
	Mean (SD)	Mean (SD)	
Inner upper arm	78.1 (17.0)	69.8 (12.8)	0.284
Volar forearm	65.1 (8.9)	67.9 (10.5)	0.581
Dorsal forearm	64.8 (12.0)	70.4 (18.9)	0.489

Note: SD, standard deviation.

^aStudent's *t* test.

3.3 OCT Item Scores

All seven items were detected and could be quantified in our sample. Figure 1 shows the OCT images representing the lowest (left column) and highest (right column) mean score per item.

3.3.1 Construct validation: skin aging

The grading results of the OCT images are shown in Table 3. Median scores ranged from 0.8 for the item “surface unevenness” to 2.5 for the item “upper dermal reflectivity.” No floor and ceiling effects were observed.

Median “SC reflectivity” was higher in older subjects on all three skin areas with differences being statistically significant for the forearm sites. “Upper dermal reflectivity” was significantly lower in the old group on both forearm areas. “Dermoepidermal contrast” and “vessel density” were higher in the old group on the forearm and comparable on the inner upper arm. “Epidermal reflectivity” and “lower dermal reflectivity” were reduced in the old group without reaching statistical significance. “Surface unevenness” increased with age on the inner upper arm and volar forearm and decreased on the dorsal forearm.

Differences between the skin areas were observed for “dermoepidermal contrast,” “vessel density,” and “surface unevenness.” Other item scores like “lower dermal reflectivity” and “upper dermal reflectivity” showed minor differences between the skin areas.

3.3.2 Interrater agreement

Interrater agreement is presented in Table 3. The highest proportions of agreement were obtained for the items “SC reflectivity,” “upper dermal reflectivity,” “dermoepidermal contrast,” and “surface unevenness” ($p_o = 83.3\%$). The lowest proportion of agreement were observed for the item “epidermal reflectivity” ($p_o = 25.0\%$).

3.3.3 Criterion validation: skin microtopography

The mean surface roughness parameters of the two age groups are presented in Table 4. R_z ranged from 38.2 μm on the volar forearm in the young group to 55.0 μm on the dorsal forearm in the old group. R_{max} ranged from 48.3 μm on the volar forearm of the young group to 74.1 μm on the dorsal forearm of the old group. SDs were always higher in the aged group. Differences between the age groups were statistically significant on the inner upper arm and volar forearm. In both age groups, surface roughness was highest on the dorsal forearm. Spearman correlation

coefficients of the item scores of “surface unevenness” were highest with R_{max} on the inner upper arm and on the volar forearm ($r_s = 0.442$ and $r_s = 0.434$). The lowest correlation coefficients were observed for R_z and R_{max} on the dorsal forearm ($r_s = 0.101$ and $r_s = 0.151$).

4 Discussion

This study introduces additional characteristics besides ET to measure skin aging in OCT images. In a sample of young and aged women, different sun-exposed and sun-protected skin areas were measured. Based on the literature and our own experience with OCT imaging, we inductively developed seven potentially observable skin characteristics.

The most common parameter measured in OCT images is ET, for which good correspondence with confocal laser scanning microscopy has been reported.¹⁵ The ET estimates obtained in our study were comparable with previously reported results.^{14,16} We were able to detect a slight thinning of the epidermis with age on the inner upper arm that confirms the results of previous studies.^{14,25} Nevertheless, ET thinning tends to occur considerably only up to the 30s¹⁶ and seems to be attenuated by the effects of photoaging.^{14,15,19}

All newly proposed characteristics were detected and could be quantified in our sample. The items had an overall good distribution of the scores and showed no floor and ceiling effects. This indicates that the item scores were suitable to discriminate between different skin characteristics.

Interrater agreement was high for the items “SC reflectivity,” “upper dermal reflectivity,” “dermoepidermal contrast,” and “surface unevenness,” indicating that these items were easier to grade leading to similar rating results. By contrast, agreement among the items “epidermal reflectivity” and “lower dermal reflectivity” was lower indicating that these items might be inadequate for assessing skin aging.

Study results demonstrated that there are age- and site-dependent differences regarding the item scores. We have chosen the construct “skin aging” to evaluate the validity of the rating results. In intrinsically aged skin, the SC turnover rate is much slower²⁶ and corneocytes are larger.^{27,28} Moreover, older subjects have a reduced amount of intercellular lipids.²⁹ These age-dependent changes may lead to alterations in the optical properties of the SC by affecting the penetration of light through the SC,³⁰ which might be a possible explanation for the higher “SC reflectivity” on both forearm sites of the old group. Whether the intensive surface reflection is really caused by the structure of the SC or by slightly different refractive indices between air and skin is ambiguous.³¹ However, we observed an obvious difference between young and older skin.

Significant differences between the age groups were also observed on both forearm sites for “upper dermal reflectivity” and “dermoepidermal contrast,” which assumes that these parameters in OCT images do most clearly change with age. The decreased “upper dermal reflectivity” which was pronounced on both forearm sites likely reflects the deposition of disorganized and highly backscattering elastin from the papillary dermis to the reticular dermis and the loss of collagen content resulting in a signal attenuation of the upper dermis.^{32,33} In close relation to less “upper dermal reflectivity” on both forearm sites is the substantial increase in “dermoepidermal contrast.” The more the reflectivity of the upper dermis decreases the higher is the ability to distinguish between epidermis and dermis.

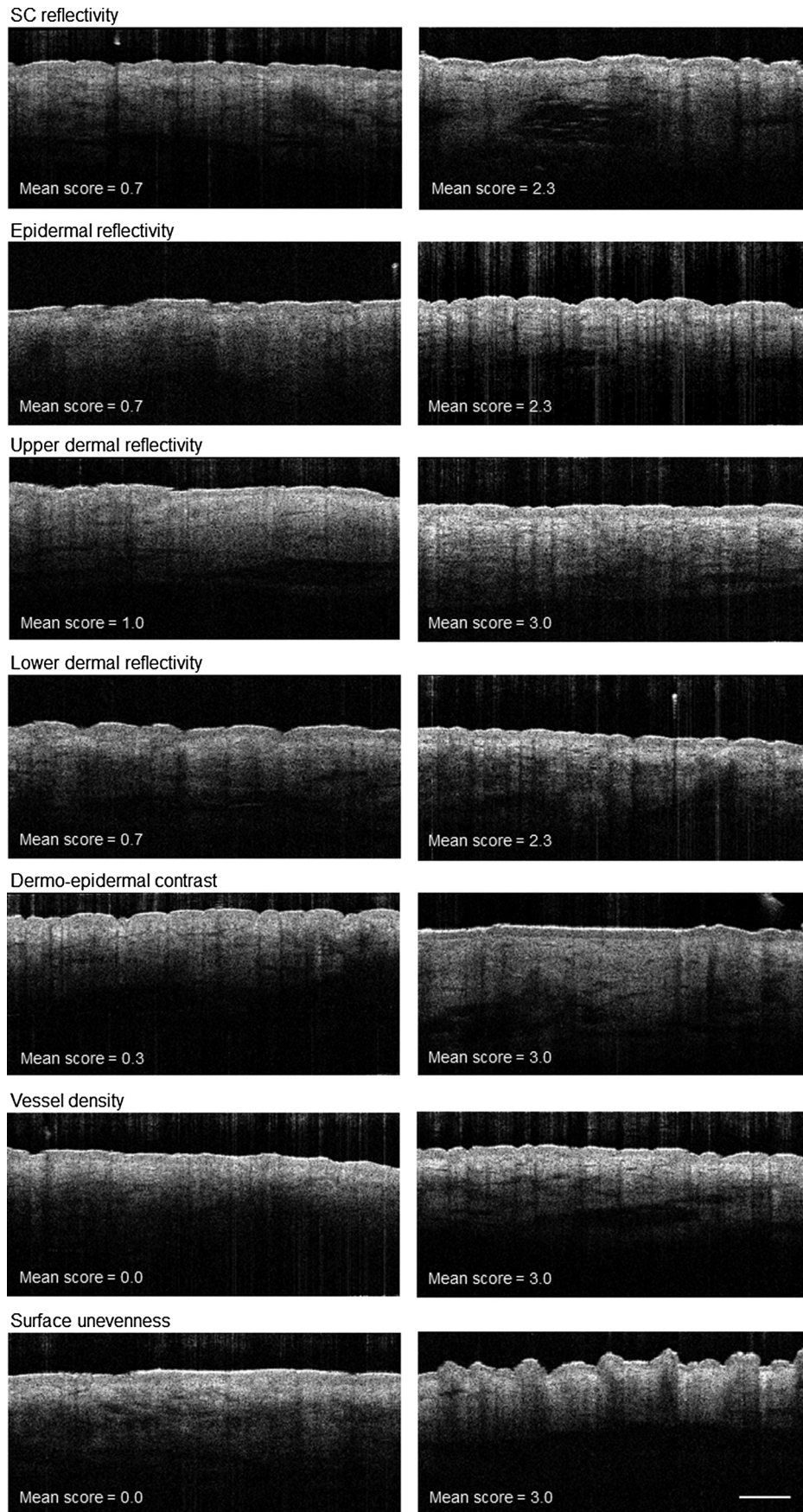


Fig. 1 Optical coherence tomography images selected among the 16 participants representing the lowest and highest mean scores per item and image. Mean scores are the averages of the scores of three raters. Scale bar 500 μm .

Table 3 Grading results of the developed OCT items.

	Young group				Old group				<i>p</i> value ^a
	\bar{x}	Interquartile range (IQR)	min; max	ρ_o (%)	\bar{x}	IQR	min; max	ρ_o (%)	
SC reflectivity									
Inner upper arm	1.3	1.0 to 1.9	0.7; 2.3	79.1	1.5	1.3 to 2.0	1.0; 2.0	70.8	0.450
Volar forearm	1.7	1.3 to 1.7	1.0; 1.7	70.8	2.0	1.7 to 2.3	1.3; 2.3	66.6	0.020
Dorsal forearm	1.3	1.0 to 1.7	1.0; 2.0	70.8	1.7	1.7 to 2.2	1.7; 2.3	66.6	0.024
Epidermal reflectivity									
Inner upper arm	1.3	1.1 to 1.3	1.0; 1.7	62.5	1.3	1.3 to 1.7	1.0; 2.0	62.5	0.244
Volar forearm	2.0	1.4 to 2.0	1.3; 2.3	45.8	1.3	1.1 to 1.3	1.0; 1.7	75.0	0.007
Dorsal forearm	1.7	1.4 to 2.0	1.0; 2.0	25.0	1.3	0.8 to 1.6	0.7; 2.0	58.3	0.083
Upper dermal reflectivity									
Inner upper arm	2.0	1.7 to 2.3	1.0; 2.7	70.8	1.7	1.2 to 2.0	1.0; 2.0	62.5	0.206
Volar forearm	2.5	2.1 to 2.7	1.3; 3.0	75.0	1.7	1.1 to 2.0	0.7; 2.3	79.1	0.013
Dorsal forearm	2.2	2.0 to 2.3	1.3; 2.7	79.1	1.7	1.3 to 1.9	1.0; 2.0	54.1	0.013
Lower dermal reflectivity									
Inner upper arm	1.7	1.4 to 1.7	1.3; 1.7	66.6	1.3	1.1 to 1.6	1.0; 2.0	79.1	0.090
Volar forearm	1.7	1.3 to 2.0	1.0; 2.3	50.0	1.5	1.0 to 1.7	0.7; 2.3	62.5	0.308
Dorsal forearm	1.5	1.3 to 1.7	1.3; 2.0	62.5	1.3	1.3 to 1.9	1.3; 2.3	70.8	0.907
Dermoepidermal contrast									
Inner upper arm	2.0	1.8 to 2.6	1.7; 2.7	79.1	1.8	1.4 to 2.0	0.7; 2.3	79.1	0.128
Volar forearm	1.3	0.7 to 1.9	0.7; 2.0	79.1	2.2	1.5 to 2.3	0.7; 2.7	75.0	0.037
Dorsal forearm	1.0	0.7 to 1.3	0.3; 3.0	83.3	1.5	1.1 to 1.9	1.0; 3.0	70.8	0.047
Vessel density									
Inner upper arm	1.7	1.1 to 2.0	0.7; 2.3	79.1	1.7	1.3 to 2.5	1.0; 3.0	66.6	0.632
Volar forearm	1.0	0.5 to 1.3	0.0; 1.7	58.3	2.0	0.8 to 2.3	0.3; 2.3	83.3	0.111
Dorsal forearm	0.7	0.3 to 0.9	0.0; 1.3	62.5	1.2	0.5 to 1.6	0.3; 2.3	75.0	0.088
Surface unevenness									
Inner upper arm	0.8	0.1 to 1.6	0.0; 2.0	83.3	1.8	1.2 to 2.3	0.7; 3.0	79.1	0.030
Volar forearm	1.2	0.8 to 1.3	0.3; 2.0	66.6	1.8	1.0 to 2.6	1.0; 2.7	83.3	0.097
Dorsal forearm	1.5	0.3 to 1.7	0.0; 1.7	70.8	1.2	0.8 to 1.3	0.0; 2.0	83.3	0.669

Note: \bar{x} , median; IQR, interquartile range; min, minimum; max, maximum; ρ_o , interrater agreement; and SC, stratum corneum.

^aMann–Whitney *U* test.

“Lower dermal reflectivity” seemed to be neither related to age nor to sun exposure. This finding is likely to be explained by the limited penetration depth and lateral resolution of the OCT signal leading to an increased signal noise and a diffuse appearance of the deeper dermis.

We expected to observe age- and site-dependent differences in “vessel density” because horizontal cutaneous vessels have been shown to be increased in the elderly.³⁴ In addition, there is evidence that photodamaged skin exhibits reduced numbers of dermal vessels compared to intrinsically aged skin.³⁵ On

Table 4 Skin surface roughness parameters R_z (μm) and R_{max} (μm) measured using Visioscan® VC98.

	Young		Old		Correlation with "surface unevenness" r_s
	Mean (SD)	Mean (SD)	p value ^a		
R_z					
Inner upper arm	39.1 (6.2)	53.3 (9.5)	0.003		0.412
Volar forearm	38.2 (4.3)	46.5 (7.1)	0.013		0.351
Dorsal forearm	48.6 (3.3)	55.0 (11.2)	0.148		0.101
R_{max}					
Inner upper arm	50.0 (7.6)	69.0 (11.1)	0.001		0.442
Volar forearm	48.3 (5.0)	60.5 (9.0)	0.005		0.434
Dorsal forearm	65.0 (5.6)	74.1 (14.5)	0.122		0.151

Note: SD, standard deviation and r_s , Spearman's correlation coefficient.

^aStudent's t test.

the other hand, an increased scattering coefficient of the dermis can lead to the reduction of dermal reflectivity thus affecting the ability to visualize blood vessels.³⁶ However, an age- and site-dependent change in "vessel density" could be shown in our sample supporting the construct validity of this item.

We observed an increase in "surface unevenness" in older subjects indicating a rougher and more folded skin surface in this age group. Epidermal changes and dermal degeneration processes during aging are considered to promote increased skin roughness.^{37,38} We could confirm this finding by Visioscan® measurements. R_z and R_{max} are regarded as the most reliable roughness parameters for quantification of the skin surface topography²² and were, therefore, chosen as reference standards for criterion validation in this study. Mean R_z and R_{max} estimates were similar to previous findings in young and old women.^{22,23} All measured roughness estimates increased with age in this study, which is in line with previously reported studies.^{39,40} Validity of the item "surface unevenness" was demonstrated by correlation with both roughness estimates. The item scores were associated with R_z and R_{max} on the inner upper arm and volar forearm, supporting that these estimates measure a similar concept on these sun-protected skin areas. In conjunction with a slightly lower surface unevenness score on the photoaged dorsal forearm skin in the old group, our results support the hypothesis that chronic UV exposure reduces the effect of intrinsic aging on this skin area,⁴¹ indicating that sun damage counteracts increasing roughness during aging. Furthermore, the limited range of R_z and R_{max} values at the dorsal forearm attenuates observed validity coefficients thus explaining the low correlation.

4.1 Limitations

This explorative study was conducted with a small number of subjects to obtain first indicators about possible characteristics of OCT images that might be related to changes due to skin aging. Generalizability of the results is limited and larger

confirmatory studies are needed. In order to reduce a possible bias due to gender and ethnicity, we included female Caucasians only. Finally, comparability with other OCT devices might be limited.

4.2 Conclusion

This study describes new quantifiable skin characteristics of OCT images besides ET. The items "SC reflectivity," "upper dermal reflectivity," "dermoepidermal contrast," and "surface unevenness" have shown sufficient interrater agreement and the ability to differentiate between age groups, thus being considered as the best candidates for measuring skin aging on OCT images.

Acknowledgments

The study was supported by the Clinical Research Center for Hair and Skin Science.

References

1. L. H. Kligman, "Photoaging. Manifestations, prevention, and treatment," *Clin. Geriatr. Med.* **5**(1), 235–251 (1989).
2. J. Uitto, "The role of elastin and collagen in cutaneous aging: intrinsic aging versus photoexposure," *J. Drugs Dermatol.* **7**(2 Suppl), s12–16 (2008).
3. M. A. Farage et al., "Intrinsic and extrinsic factors in skin ageing: a review," *Int. J. Cosmet. Sci.* **30**(2), 87–95 (2008).
4. M. Coma et al., "Methods for diagnosing perceived age on the basis of an ensemble of phenotypic features," *Clin. Cosmet. Investig. Dermatol.* **7**, 133–137 (2014).
5. A. Nkengne et al., "Influence of facial skin attributes on the perceived age of Caucasian women," *J. Eur. Acad. Dermatol. Venereol.* **22**(8), 982–991 (2008).
6. T. Omi et al., "Histological evidence for skin rejuvenation using a combination of pneumatic energy, broadband light, and growth factor therapy," *J. Cosmet. Laser Ther.* **12**(5), 222–226 (2010).
7. J. Lademann et al., "Optical investigations to avoid the disturbing influences of furrows and wrinkles quantifying penetration of drugs and cosmetics into the skin by tape stripping," *J. Biomed. Opt.* **10**(5), 054015 (2005).
8. E. Sattler, R. Kastle, and J. Welzel, "Optical coherence tomography in dermatology," *J. Biomed. Opt.* **18**(6), 061224 (2013).
9. T. Gambichler, V. Jaedicke, and S. Terras, "Optical coherence tomography in dermatology: technical and clinical aspects," *Arch. Dermatol. Res.* **303**(7), 457–473 (2011).
10. N. S. Greaves et al., "Optical coherence tomography: a reliable alternative to invasive histological assessment of acute wound healing in human skin?," *Br. J. Dermatol.* **170**(4), 840–850 (2014).
11. V. R. Korde et al., "Using optical coherence tomography to evaluate skin sun damage and precancer," *Lasers Surg. Med.* **39**(9), 687–695 (2007).
12. L. M. Vasquez-Pinto et al., "Optical coherence tomography applied to tests of skin care products in humans—a case study," *Skin Res. Technol.* **21**(1), 90–93 (2015).
13. J. K. Barton et al., "Investigating sun-damaged skin and actinic keratosis with optical coherence tomography: a pilot study," *Technol. Cancer Res. Treat.* **2**(6), 525–535 (2003).
14. T. Gambichler et al., "In vivo data of epidermal thickness evaluated by optical coherence tomography: effects of age, gender, skin type, and anatomic site," *J. Dermatol. Sci.* **44**(3), 145–152 (2006).
15. S. Neerken et al., "Characterization of age-related effects in human skin: A comparative study that applies confocal laser scanning microscopy and optical coherence tomography," *J. Biomed. Opt.* **9**(2), 274–281 (2004).
16. T. Tsugita et al., "Positional differences and aging changes in Japanese woman epidermal thickness and corneal thickness determined by OCT (optical coherence tomography)," *Skin Res. Technol.* **19**(3), 242–250 (2013).

17. N. Aoi et al., "Ultrasound assessment of deep tissue injury in pressure ulcers: possible prediction of pressure ulcer progression," *Plast. Reconstr. Surg.* **124**(2), 540–550 (2009).
18. J. Lademann et al., "Application of optical non-invasive methods in skin physiology: a comparison of laser scanning microscopy and optical coherent tomography with histological analysis," *Skin Res. Technol.* **13**(2), 119–132 (2007).
19. M. Mogensen et al., "Morphology and epidermal thickness of normal skin imaged by optical coherence tomography," *Dermatology* **217**(1), 14–20 (2008).
20. M. Kuck et al., "Evaluation of optical coherence tomography as a non-invasive diagnostic tool in cutaneous wound healing," *Skin Res. Technol.* **20**(1), 1–7 (2014).
21. D. L. Streiner, G. R. Norman, and J. Cairney, "Scaling responses," in *Health Measurement Scales. A Practical Guide to Their Development and Use*, pp. 38–73, Oxford University Press, Oxford (2015).
22. C. Trojahn et al., "Reliability and validity of two *in vivo* measurements for skin surface topography in aged adults," *Skin Res. Technol.* **21**(1), 54–60 (2014).
23. J. Kottner et al., "Comparison of two *in vivo* measurements for skin surface topography," *Skin Res. Technol.* **19**(2), 84–90 (2013).
24. J. Kottner and D. L. Streiner, "The difference between reliability and agreement," *J. Clin. Epidemiol.* **64**(6), 701–702; author reply 702 (2011).
25. C. Longo et al., "Skin aging: *in vivo* microscopic assessment of epidermal and dermal changes by means of confocal microscopy," *J. Am. Acad. Dermatol.* **68**(3), e73–82 (2013).
26. G. L. Grove and A. M. Kligman, "Age-associated changes in human epidermal cell renewal," *J. Gerontol.* **38**(2), 137–142 (1983).
27. J. L. Leveque et al., "*In vivo* studies of the evolution of physical properties of the human skin with age," *Int. J. Dermatol.* **23**(5), 322–329 (1984).
28. M. Kawai, G. Imokawa, and M. Mizoguchi, "Physiological analysis of the facial skin by corneocyte morphology and stratum corneum turnover," *Nihon Hifuka Gakkai Zasshi* **99**(9), 999–1006 (1989).
29. J. Rogers et al., "Stratum corneum lipids: the effect of ageing and the seasons," *Arch. Dermatol. Res.* **288**(12), 765–770 (1996).
30. J. L. Solan and K. Laden, "Factors affecting the penetration of light through stratum corneum," *J. Soc. Cosmet. Chem.* **28**(3), 125–137 (1977).
31. J. Welzel et al., "Changes in function and morphology of normal human skin: evaluation using optical coherence tomography," *Br. J. Dermatol.* **150**(2), 220–225 (2004).
32. M. El-Domyati et al., "Intrinsic aging vs. photoaging: a comparative histopathological, immunohistochemical, and ultrastructural study of skin," *Exp. Dermatol.* **11**(5), 398–405 (2002).
33. J. H. Chung et al., "Modulation of skin collagen metabolism in aged and photoaged human skin *in vivo*," *J. Invest. Dermatol.* **117**(5), 1218–1224 (2001).
34. R. I. Kelly et al., "The effects of aging on the cutaneous microvasculature," *J. Am. Acad. Dermatol.* **33**(5 Pt 1), 749–756 (1995).
35. J. H. Chung et al., "Differential effects of photoaging vs intrinsic aging on the vascularization of human skin," *Arch. Dermatol.* **138**(11), 1437–1442 (2002).
36. T. Gambichler et al., "Applications of optical coherence tomography in dermatology," *J. Dermatol. Sci.* **40**(2), 85–94 (2005).
37. E. M. Wurm et al., "*In vivo* assessment of chronological ageing and photoageing in forearm skin using reflectance confocal microscopy," *Br. J. Dermatol.* **167**(2), 270–279 (2012).
38. S. G. Lagarrigue et al., "*In vivo* quantification of epidermis pigmentation and dermis papilla density with reflectance confocal microscopy: variations with age and skin phototype," *Exp. Dermatol.* **21**(4), 281–286 (2012).
39. K. De Paepe et al., "Microrelief of the skin using a light transmission method," *Arch. Dermatol. Res.* **292**(10), 500–510 (2000).
40. U. Jacobi et al., "*In vivo* determination of skin surface topography using an optical 3D device," *Skin Res. Technol.* **10**(4), 207–214 (2004).
41. C. Edwards, R. Heggie, and R. Marks, "A study of differences in surface roughness between sun-exposed and unexposed skin with age," *Photodermatol. Photoimmunol. Photomed.* **19**(4), 169–174 (2003).

Carina Trojahn received her diploma in human biology from the University of Marburg in 2010 and worked as a project manager of clinical studies in the field of dermatology and cosmetic science. In 2013, she started her PhD at the Clinical Research Center for Hair and Skin Science at the Department of Dermatology and Allergy at the Charité-Universitätsmedizin Berlin. Her research focuses on validation of methods for measuring structural and functional changes during skin aging.

Gabor Dobos received his degree in medicine from the Semmelweis University of Budapest in 2012. In the same year, he started his PhD at the Clinical Research Center for Hair and Skin Science at the Department of Dermatology and Allergy at the Charité-Universitätsmedizin Berlin. His research focuses on skin diseases of the elderly, validation of measurement techniques, and clinical scores in the context of skin ageing.

Claudia Richter received her master's of English philology from the University of Halle-Wittenberg in 2007 and worked as study coordinator of clinical studies in the field of dermatology. In 2014, she started her PhD at the Clinical Research Center for Hair and Skin Science at the Department of Dermatology and Allergy at the Charité-Universitätsmedizin Berlin. Her research focuses on skin barrier function, skin physiological measurement techniques, and dermatological disorders, e.g., acne vulgaris.

Ulrike Blume-Peytavi is a full university professor and the executive medical director of the Department of Dermatology and Allergy at the Charité-Universitätsmedizin Berlin. She is the director of the Clinical Research Center for Hair and Skin Science. In 2013, she became the president of the German Association of Pediatric Dermatology. Her research focuses on skin and hair physiology, pediatric dermatology, follicular targeting, and transcutaneous vaccination.

Jan Kottner is the scientific director of the Clinical Research Center for Hair and Skin Science at the Department of Dermatology and Allergy at the Charité-Universitätsmedizin Berlin. He is an executive board member of the EPUAP. His research interests are skin barrier maintenance, protection, restoration, and skin problems and skin care interventions in aged and care-dependent subjects. He also has special expertise in the development and validation of clinical diagnoses, classifications, and scores.